

12

AUTOPSY REPORT

No. 2011-06709
LOGAN, DARRELL

I performed an autopsy on the body of



at THE DEPARTMENT OF CORONER

Los Angeles, California on October 17-18, 2011 1300
(Date) (Time)

From the anatomic findings and pertinent history I ascribe the death to:

(A) Multiple gunshot wounds

DUE TO OR AS A CONSEQUENCE OF

(B)

DUE TO OR AS A CONSEQUENCE OF

(C)

DUE TO OR AS A CONSEQUENCE OF

(D)

OTHER CONDITIONS CONTRIBUTING BUT NOT RELATED TO THE IMMEDIATE CAUSE OF DEATH:

Anatomical Summary:

The decedent sustained 11 gunshot wounds (GSWs). All entered the right back side of the body (except GSW 7, unknown direction). Five bullets are recovered subcutaneously (palpable), and are medium caliber and copper jacketed. Soot, stippling, searing, or muzzle stamp was not seen on any of the GSWs. 600 cc left hemothorax and ~50 cc hemoperitoneum are seen.

Gunshot wound #1

Non-fatal GSW entering the right back.
Bullet fractures the right scapula.
Mushroomed bullet recovered from the top of the right trapezius muscle.
Direction is superior, slightly anterior and right

Gunshot wound #2

Fatal GSW entering the mid back.
Bullet penetrates the left 10th intercostal space near costovertebral angle, heart (3/4" wound of posterior left ventricle, 1/2" wound of anteroapical left ventricle), pericardium, left anterior 5th rib.

Projectile recovered from left anterior axilla (jacket and bullet separated, 1 1/2" apart, bullet is superior to jacket)

Direction is right to left, slightly anterior.

12

AUTOPSY REPORT

No. 2011-06709
LOGAN, DARRELL

Page 2

Gunshot wound #3

Fatal GSW entering the right lateral back and exiting right upper chest.

Bullet penetrates the right posterior 9th rib, right lower and upper lung, exits the 1st intercostal space.

Direction is superior and slightly anterior.
No projectile recovered.

Gunshot wound #4

Fatal GSW entering the right posterior axilla and exiting left chest (1" left of nipple).

Bullet penetrates the right posterolateral 9th intercostal space, right lower lung, aorta (just above diaphragm), left lower lung.

Direction is right to left, slightly superior/anterior
No projectile recovered.

Gunshot wound #5

Fatal GSW entering the right flank (mid axillary) and exiting left upper abdomen.

Bullet penetrates the right lateral 10th rib, diaphragm, liver (3" gaping transverse wound).

Direction is right to left and slightly anterior
No projectile recovered.

Gunshot wound #6

Fatal GSW entering the right buttock.

Bullet penetrates the sacrum, right psoas muscle, right kidney (inferior pole), right liver (2" wound from posterior to superior liver), right diaphragm, right lower lung, right anterior 6th rib.

Projectile (relatively intact) recovered from ¾" under the right nipple.

Direction is superior and slightly anterior.

Gunshot wound #7

Non-fatal thru-and-thru GSW of left medial knee.
Bullet penetrates only skin. Two nearly identical round GSWs separated by a thin bridge of skin. Dried margins.

Direction is undetermined.
No projectile recovered.

Gunshot wound #8

Non-fatal thru-and-thru GSW entering the right posterolateral thigh and exiting upper anterior thigh.
Bullet penetrates skin and muscle. No fracture detected.

Direction is anterior and superior.
No projectile recovered.

Gunshot wound #9

Non-fatal thru-and-thru GSW entering the right lateral thigh and exiting anterior thigh.
Bullet penetrates skin and muscle. No fracture detected.

Direction is right to left, anterior and superior.
No projectile recovered.

Gunshot wound #10

Potentially fatal tangential GSW entering the posterior midline scalp and partially exiting left parietal scalp. The entrance wound has a right-sided marginal abrasion and external bevel. The exit wound has skin tears pointing left and raised skull chip fragments.

1 1/4 x 1/2" gutter fracture of outer table. 1 1/4 x 1" circular depressed fracture of inner table. Thin film of left subdural hemorrhage. 1/4" dural and 1/8" meningeal laceration. 1" cerebral contusion under the depressed fracture.

Base of the bullet and copper jacket recovered from scalp of tangential wound.

Direction is right to left and superior.

Gunshot wound 11

Non-fatal GSW of right thenar eminence. No fractures detected. Mushroomed bullet recovered just distal to wound, subcutaneous.

Graze wound - 1 ¼ x 3/8" graze wound of right posterolateral bicep. Wound is thinner anteriorly.

Abrasions'

- Over left brow, ¾ x ¼"
- Under left lip, ¼"
- Left temple, 1 ½" thin crescent shaped

Localization of the GSWs are on pages 5-6.

Please see separate toxicology report.

CIRCUMSTANCES:

Please see Investigator's Report.

EXTERNAL EXAMINATION:

The body is identified by toe tags and is that of an unembalmed refrigerated adult black male who appears the reported age of 32 years. The body weighs 141 pounds, measures 70 inches and is normally developed. Hydration and nutritional status are grossly normal. Examination of the skin reveals no evidence of jaundice. Small scars are seen on the right elbow and right posterior hand. Tattoos are present: 'Emani Dineh' right shoulder, 'Brenda' right chest, 'R.I.P. Mark' left shoulder, and multiple others. Rigor mortis has presumably been altered with moderate rigor of the lower extremities. No rigor of arms. Livor mortis is fixed and posterior.

The head is normal in size and shape. The scalp hair is short and black in color. There is no temporal or vertex balding. Mustache and beard are present. Examination of the eyes reveals irides that appear to be brown in color and sclerae that are white. The conjunctivae are not congested. There are no petechial hemorrhages of the conjunctivae of the lids or the sclerae. Upper and lower teeth are present and in good condition. Frenulae and oral mucosa are intact. No nasal fractures are palpated. There is no chest deformity. There is no increased anterior-posterior diameter. The abdomen is not unusual. The genitalia are those of an adult male. The external genitalia are without trauma or lesions.

EVIDENCE OF THERAPEUTIC INTERVENTION:

The following are present and are in the proper position: Endotracheal tube and bilateral antecubital IVs. There has not been post mortem intervention for organ procurement.

CLOTHING:

The body was not clothed, and the clothing was not available for examination at the time of autopsy.

TRAUMA:

For purposes of identification and convenience, injuries are arbitrarily numbered and this is not an opinion as to the order in which these wounds were sustained.

The following descriptions represent probable trajectories through the body/organs. Other combinations of entrance, bullet, exit, and organ wounds cannot be excluded since there are 6 overlapping gunshot wound paths in the torso. Due to the overlapping paths, and twisting/movement of the body during the shooting, it is not possible to determine with absolute certainty the trajectories.

All entrance wounds are round, measure $\frac{1}{4}$ ", and have marginal abrasion. All exit wounds are round with irregular edges, measure $\frac{1}{4}$ ", and have no marginal abrasion.

12

AUTOPSY REPORT

No. 2011-06709
LOGAN, DARRELL

Page 6

Table key:

All measurements are inches

TOS = from top of shoulder

ROM = right of midline

Entrance wounds

GSW#	TOS	ROM	
1	5 ½	3 ¾	
2	9	0	
3	10	4 ¼	
4	10	7	
5	14	Mid axillary	
6	23	1 ½	
7	L knee		
8	31 ¼	R thigh	
9	32	R thigh	
10	1 ½	0	
11	R Hand		

Exit wounds/bullets

GSW#	TOS	r/l	Bullet
1	0	4 r	1/5
2	8 ½	5 l	2/5
3	3 ½	4 r	
4	8	5 l	
5	13 ½	2 ½ l	
6	9	4 r	3/5
7	L knee		
8	28	Anterior thigh	
9	30 ¼	Anterior thigh	
10		Scalp	4/5
11	R Hand		5/5

12

AUTOPSY REPORT

No. 2011-06709
LOGAN, DARRELL

Page 7

INITIAL INCISION:

The body cavities are entered through the standard coronal incision and the standard Y-shaped incision. No foreign material is present in the mouth, upper airway, and trachea.

NECK:

The neck organs are removed en bloc with the tongue. No lesions are present nor is trauma of the gingiva, lips, or oral mucosa demonstrated. There is no edema of the larynx. Both hyoid bone and larynx are intact and without fractures. No hemorrhage is present in the adjacent throat organs investing fascia, strap muscles, thyroid, or visceral fascia. There are no prevertebral fascial hemorrhages. The tongue when sectioned shows no trauma. No fractures of the cervical vertebrae are present.

CHEST/ABDOMINAL CAVITY:

There are no pleural adhesions. The lungs are poorly expanded. Soft tissues of the thoracic and abdominal walls are well-preserved. The organs of the abdominal cavity have a normal arrangement and none are absent. Ascites is not present. The peritoneal cavity is without evidence of peritonitis. There are no adhesions.

SYSTEMIC AND ORGAN REVIEW:

Note: The conditions appearing in the Anatomic Summary and Description of Injuries are not necessarily repeated in the Systemic Review. The systemic review is, in essence, a description of the decedent prior to sustaining injuries. All diagrams and descriptions are made using the standard anatomic position at all times.

MUSCULOSKELETAL SYSTEM:

No abnormalities of the uninjured bony framework or muscles are identified.

CARDIOVASCULAR SYSTEM:

The thoracic and abdominal aorta have no atherosclerosis. There is no tortuosity or widening of the thoracic segment. There is no dilation of the lower abdominal segment. No aneurysm is present. The major branches of the aorta show no abnormality.

The heart weighs 290 grams. It has a normal configuration. The right ventricle is 0.3 cm, the interventricular septum is 1 cm in thickness, and the left ventricle is 1.3 cm in thickness. The chambers are normally developed and are without mural thrombosis. The valves are thin, leafy, and competent. No cardiac valve vegetations are present. Circumferences of the valve rings are within normal limits. There are no infarcts of the myocardium. There is no abnormality of the apices of the papillary musculature. There are no natural defects of the septum. The great vessels enter and leave in a normal fashion. The ductus arteriosus cannot be probed. The coronary ostia are patent, located at or below the sinotubular junction and are relatively centrally located within their respective sinuses. Serial sectioning of the coronary arteries show no atherosclerosis.

RESPIRATORY SYSTEM:

Scant secretions are found in the upper respiratory and lower bronchial passages. No froth or soot is present in the upper or lower airway. The mucosa is intact and pale. The lungs are collapsed and there is dependent congestion. The right lung weighs 260 grams and the left lung weighs 210 grams. The visceral pleurae are smooth. The pulmonary vasculature is without thromboembolism.

GASTROINTESTINAL SYSTEM:

The esophagus is intact throughout. Esophageal varices are not present. The stomach is empty and the mucosa is unremarkable. The small intestine and colon are unremarkable. The appendix is present and normal. The pancreas occupies a normal position. There is no necrosis or trauma. There is no evidence of pancreatic fibrosis or of pancreatitis.

HEPATOBIILIARY SYSTEM:

The liver weighs 1130 grams, is of average size, and is red-brown in color. The consistency of the parenchyma is firm. The cut surface is smooth. There is no evidence of cirrhosis. There is a normal lobular arrangement. The gallbladder is present. The wall is thin and pliable. It contains a moderate amount of bile and no calculi.

URINARY SYSTEM:

The right kidney weighs 100 grams and the left kidney weighs 100 grams. The kidneys are normally situated and the capsules strip easily revealing a surface that is smooth and glistening. The corticomedullary demarcation is preserved. The pyramids are not remarkable. The peripelvic fat is not increased. The ureters are without dilation or obstruction and pursue their normal course. The urinary bladder is unremarkable. It contains approximately 30 cc of cloudy, yellow urine. The urine is not tested by the dipstick method.

GENITAL SYSTEM:

The prostate is without enlargement or nodularity. Both testes are in the scrotum and are unremarkable and without trauma.

HEMOLYMPHATIC SYSTEM:

The spleen weighs 100 grams and is of average size. The capsule is intact. The parenchyma is dark red and soft. There is no increased follicular pattern. Lymph nodes throughout the body are small and inconspicuous. The bone is not remarkable. The bone marrow of the rib is unremarkable.

ENDOCRINE SYSTEM:

The thyroid, adrenal, and pituitary glands are unremarkable. The parathyroid glands are not identified. The thymus is the usual appearance for the age.

SPECIAL SENSES:

The eyes are not dissected. The middle and inner ear are not dissected.

HEAD AND CENTRAL NERVOUS SYSTEM:

The brain weighs 1400 grams. The leptomeninges are thin and transparent. A normal convolutionary pattern is observed. Coronal sectioning demonstrates a uniformity of cortical gray thickness. The cerebral hemispheres are symmetrical. There is no softening, discoloration, or hemorrhage of the white matter. The basal ganglia are intact. Anatomic landmarks are preserved. The ventricular system has a normal appearance without dilation or distortion. Pons, medulla, and cerebellum are unremarkable. There is no evidence of uncal or cerebellar herniation. Vessels at the base of the brain have a normal pattern of distribution. There are no aneurysms. The cerebral arteries are without arteriosclerosis.

SPINAL CORD:

The cord is not dissected.

EVIDENCE COLLECTION:

5 projectiles are recovered from the decedent, each placed separately in labeled envelopes, sealed with red evidence tape. The 5 envelopes are placed in 1 large white envelope, signed and dated across the seal, and placed in evidence drop box on 10/18/11.

HISTOLOGIC SECTIONS:

Representative sections from various organs are preserved in one storage jar.

TOXICOLOGY:

Samples of chest and femoral blood, bile, urine, and vitreous are submitted to the laboratory for homicide screen. An EDTA tube is collected for blood typing.

12

AUTOPSY REPORT

No. 2011-06709
LOGAN, DARRELL

Page 11

SPECIAL PROCEDURES:

None.

PHOTOGRAPHY:

At scene photos are not available. Photographs have been taken prior to the course of the autopsy. Trajectory rod photos are taken after removal of chest plate, but before removal of organs. If there is discrepancy between diagrams and photos, consider the diagrams to be more accurate.

RADIOLOGY:

13 x-rays are taken and show the bullets described above.

WITNESSES:


Sergeant Fredendall and partner, LASD.
DA investigator Frum.

DIAGRAMS USED:

Diagram forms #20, 20, 20, 21, 22, 23, 34, and 43 were used during the performance of the autopsy. Coroner diagrams are not intended to be facsimiles nor are they drawn to scale.

OPINION:

The cause of death is multiple gunshot wounds. The manner of death is homicide.

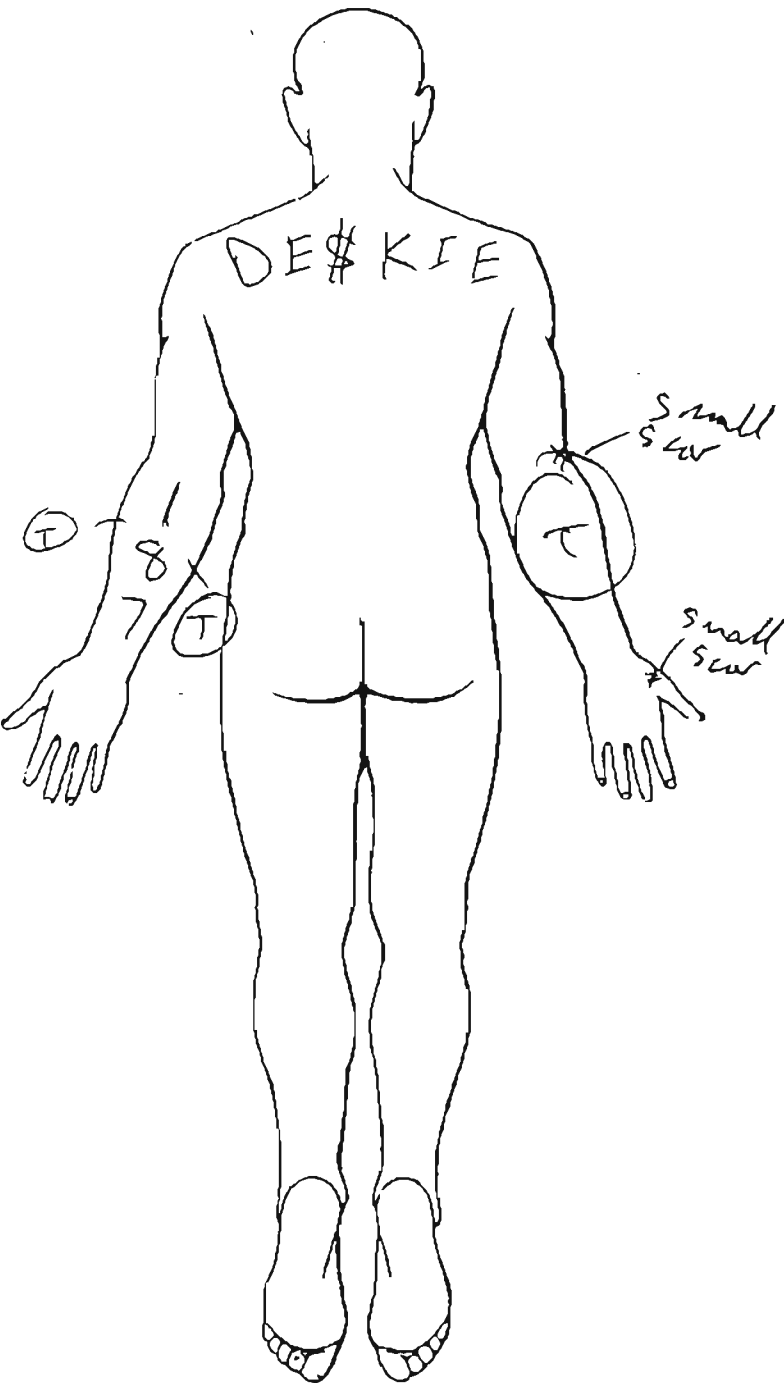
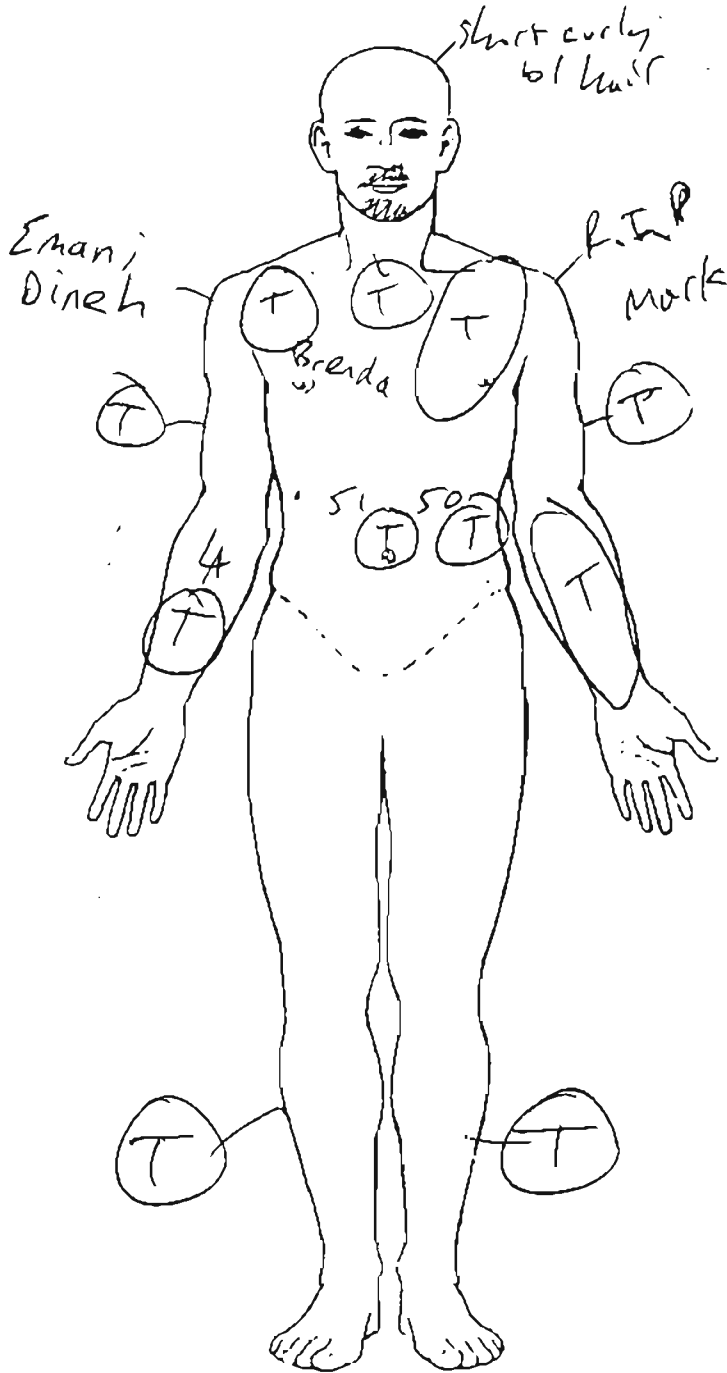

Kevin Young, M.D.
Deputy Medical Examiner

10/19/11
Date

20
1/8

Black skin m.
ID
⊕ = Tattoo

2011-06709
LUGAN, GARRELL L
HOMI
LASD-HOMI 117



Date _____

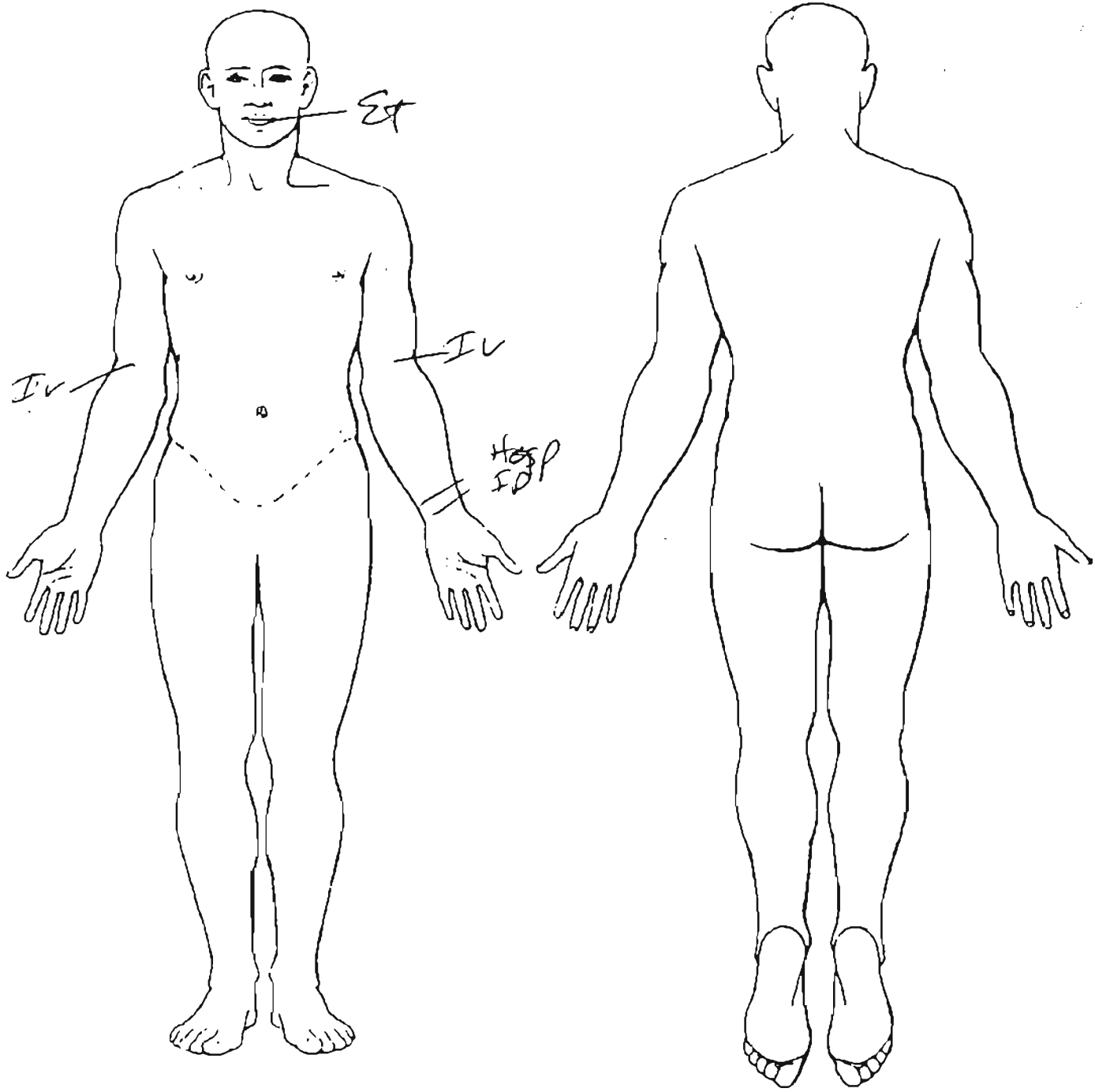
[Signature] 6/18/11 M.D.
Deputy Medical Examiner

20
2/8

Medical

2011-06709
LOGAN, DARRELL L
HOMI
LASD-HOMI

11



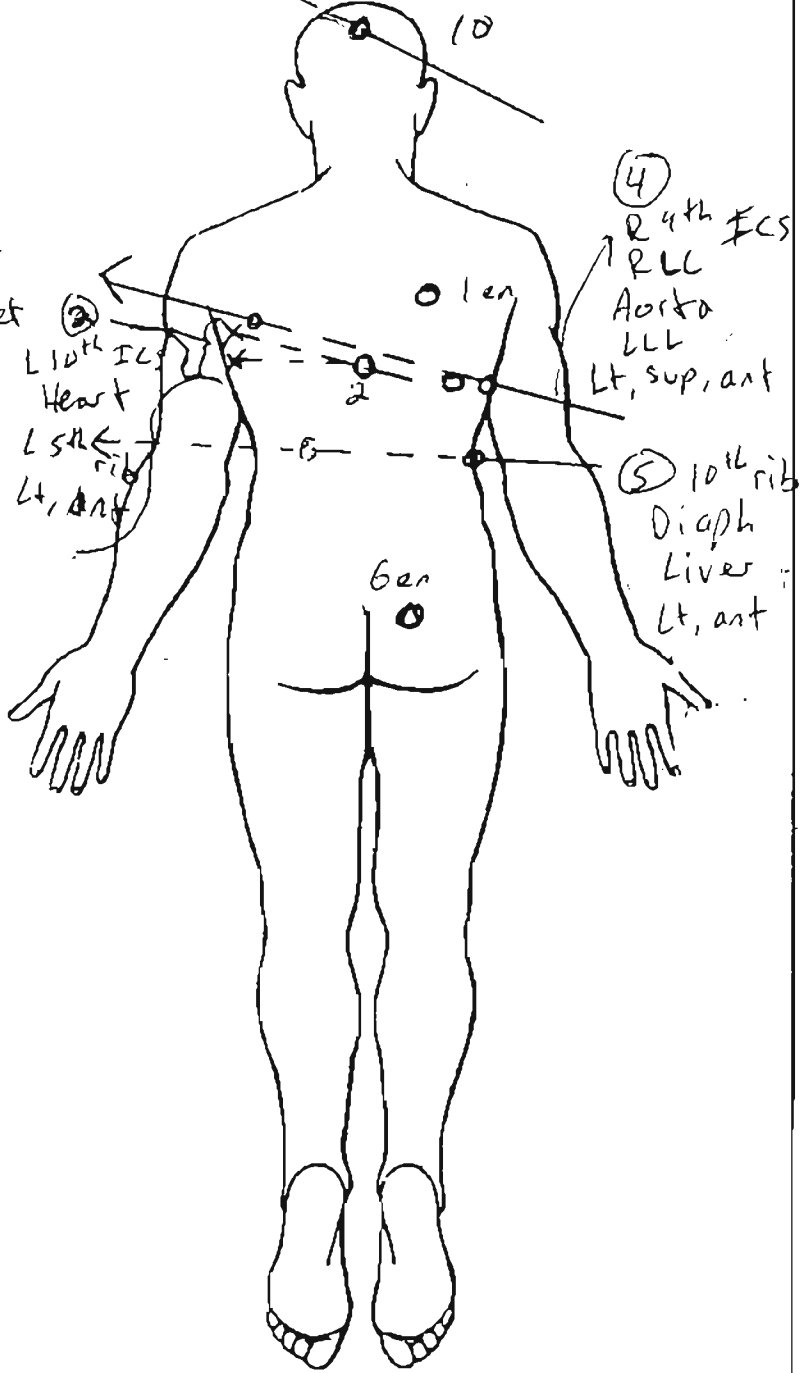
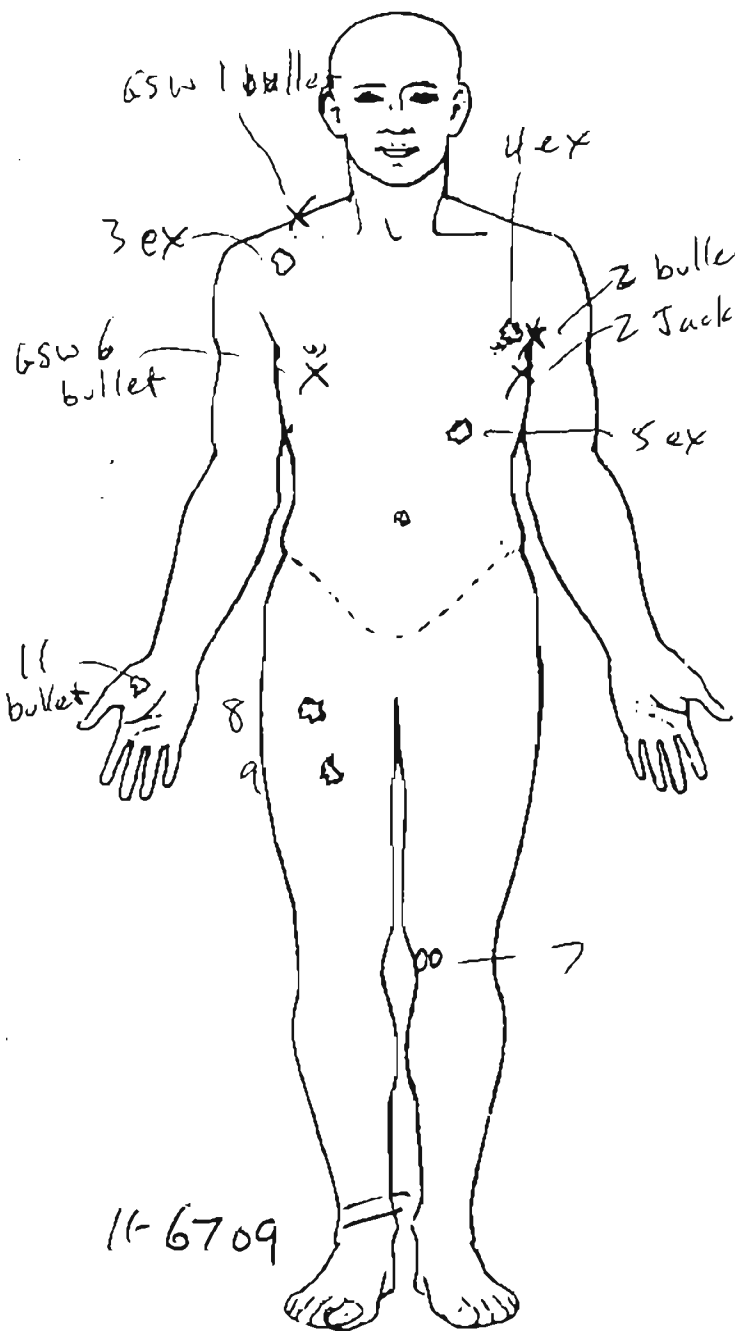
Date _____

Ky 10/18/11 _____ M.D.
Deputy Medical Examiner

20
3/8

GSW 1-11

#011-06709
#011-06709
LOGAN, GARRELL L
DHI
LASD-HOMI 117



11-6709

Logan

Date
 10/18/11
 Deputy Medical Examiner M.D.

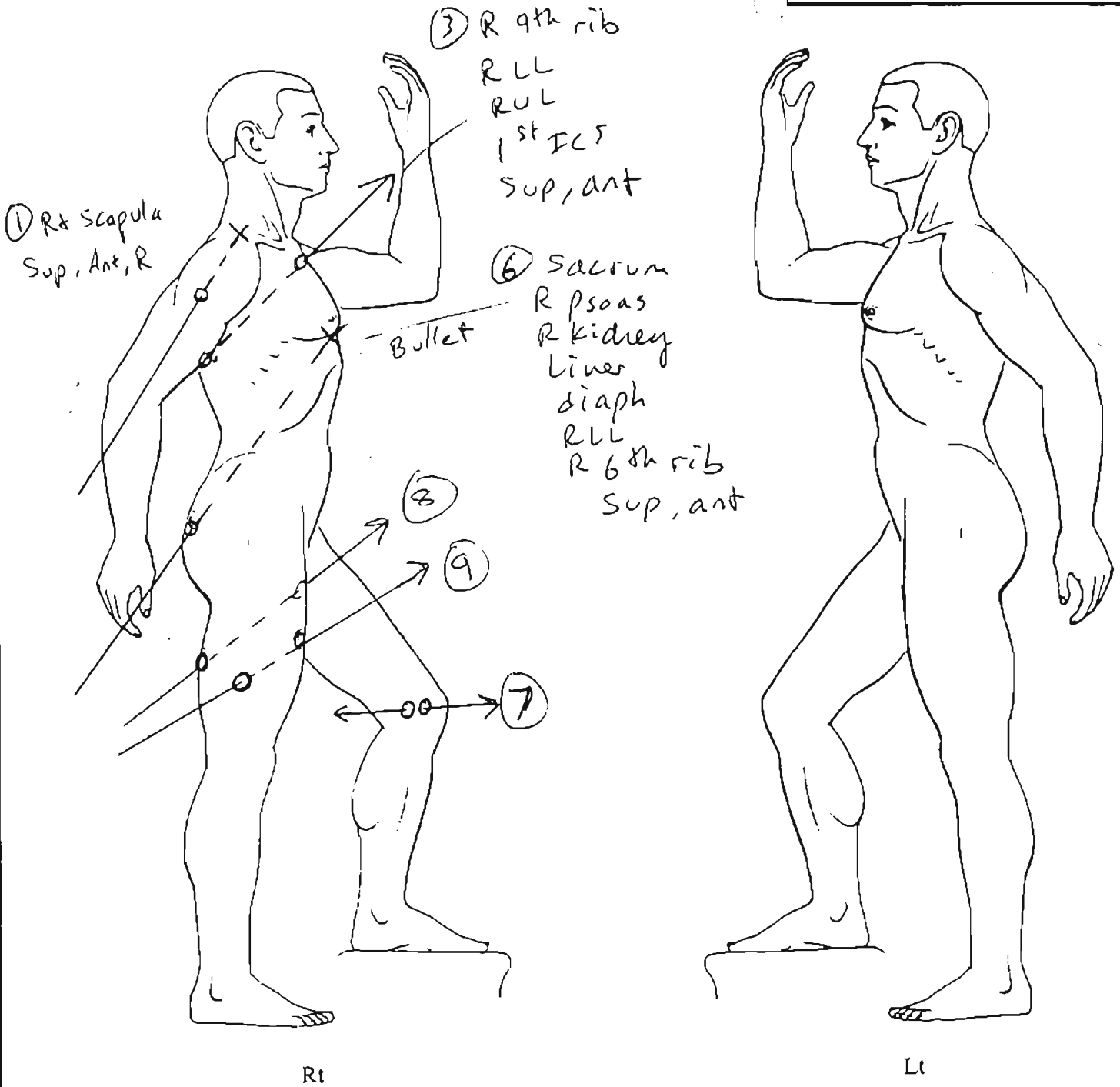
21

4/8

GSWs #1, 3, 6-9

2011-06709
LOTTAN, DARRELL L
POMI
LASO-HOHI

11



[Signature] 10/18/11

Deputy Medical Examiner

M.D.

22

5/8

2011-06709

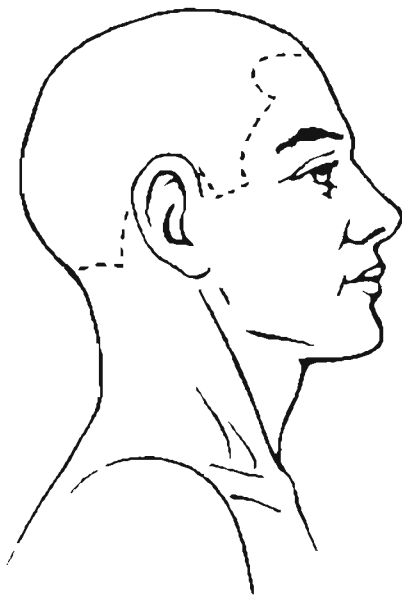
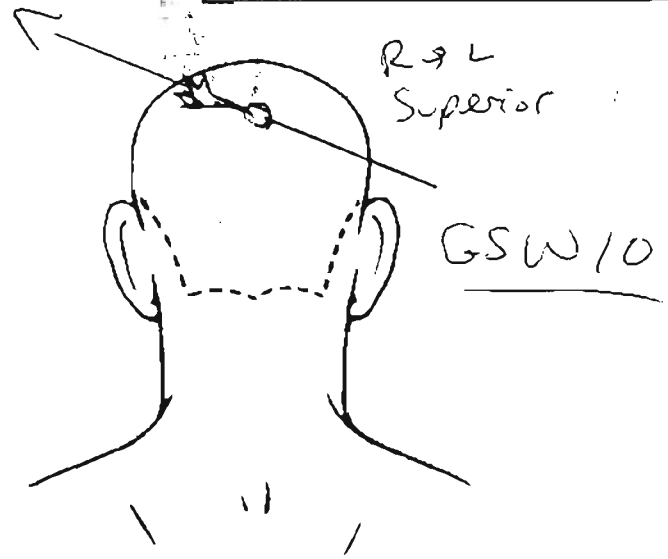
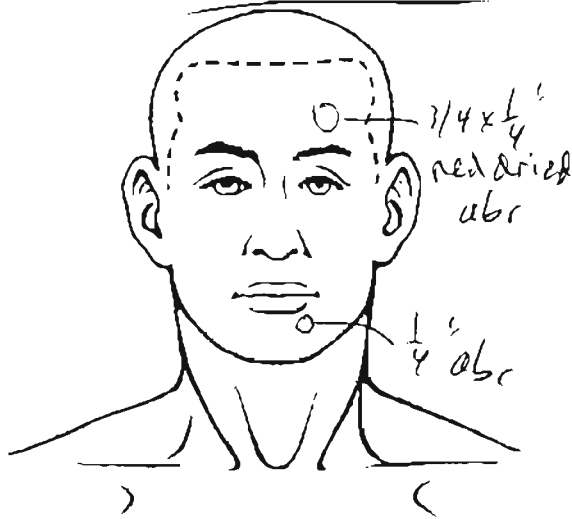
LOGAN, DARRELL L

HOMI

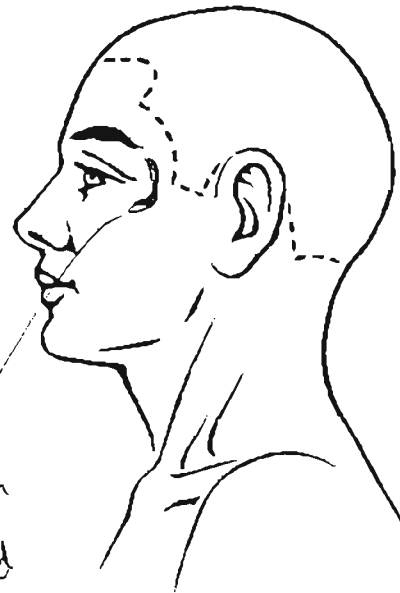LA SO-HOMI

11

Abrasions



1/2" thin
crescent
red dried
abr



Date

[Signature] 6/18/11

M.D.

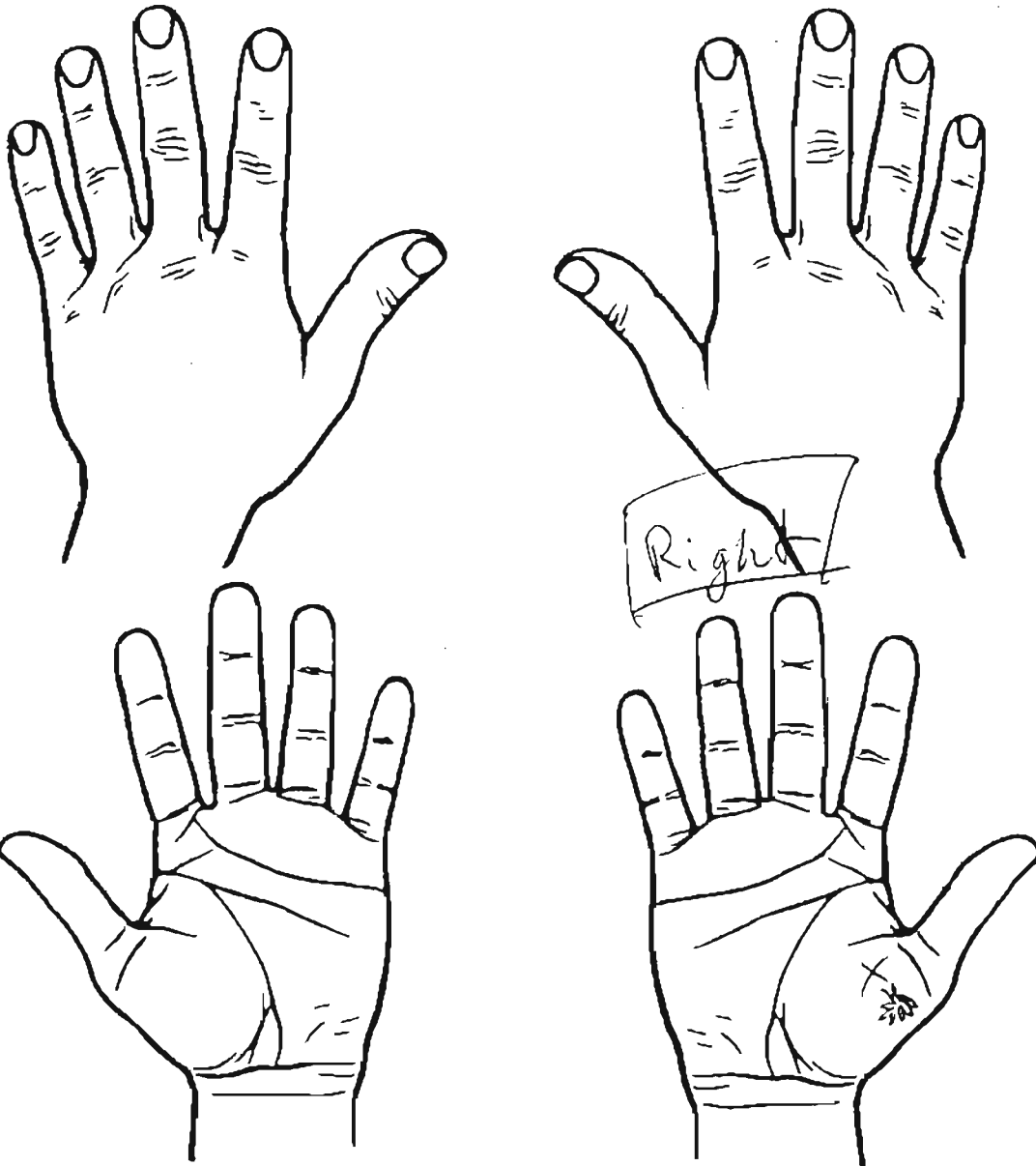
Deputy Medical Examiner

23
6/8

GSW 11

2011-016 117
LESLIE BARRELL L
MOM
LASO-0001

117



Hy 10/18/11

Deputy Medical Examiner

M.D.

34

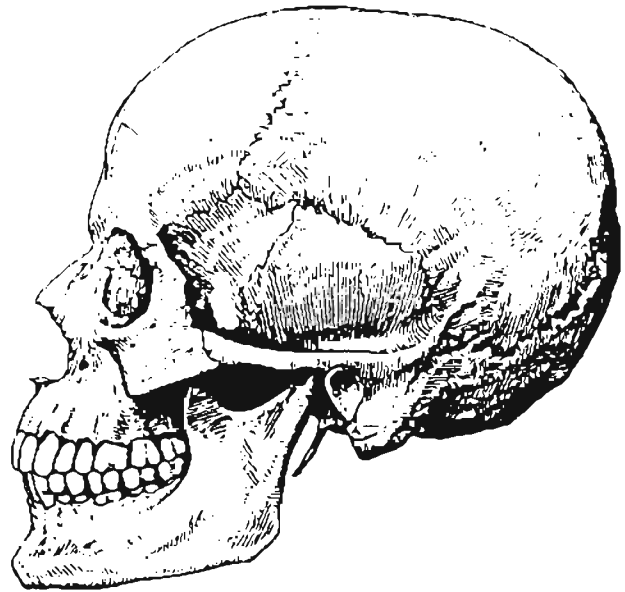
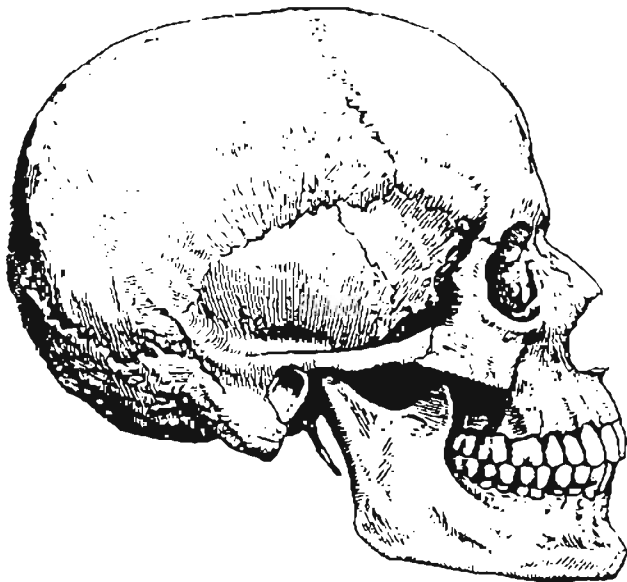
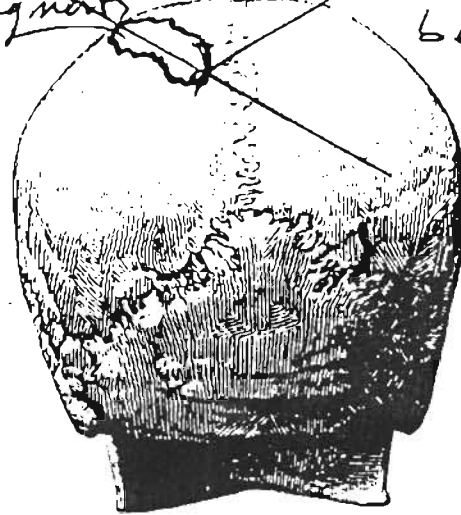
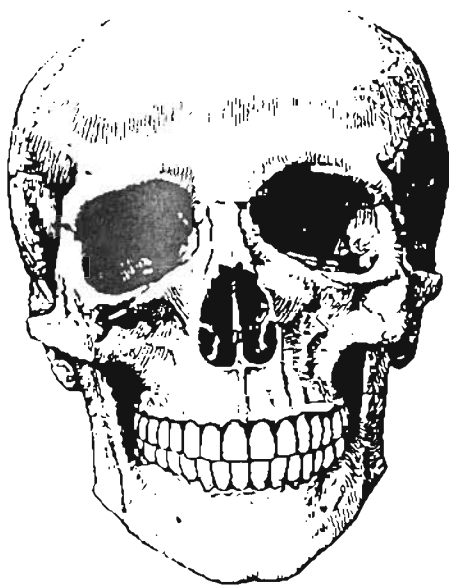7/8

GSW 10

2011-06709
LOGAN, DARRELL L
HOHI
LASD-HOHI

11

raised skull
chip fragments
external
level



[Signature] 10/18/11

M.D.
Deputy Medical Examiner

MISCELLANEOUS WORK SHEET

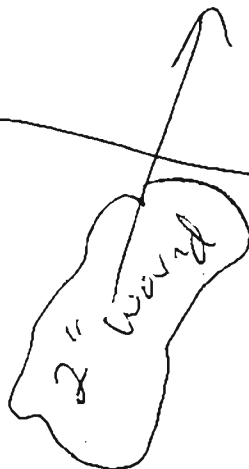43

8/8

2011-06707
LOGAN, DARRELL L
HOMI
LASD-HOMI

117

G S W 6



3" gaping

G S W
5

Date

10/18/11

117

15

AUTOPSY CLASS: A B C Examination Only D

FAMILY OBJECTION TO AUTOPSY

Date: Oct 17-18 Time: 1300 Dr. Young
(Print)

FINAL ON: 10/18/11 By: Young
(Print)

APPROXIMATE INTERVAL BETWEEN ONSET AND DEATH

1-15777
1-15777
1-15777
1-15777

117

DEATH WAS CAUSED BY: (Enter only one cause per line for A, B, C, and D)

IMMEDIATE CAUSE:
(A) Multiple gunshot wounds Min

Age: 32 Gender: Male Female

DUE TO, OR AS A CONSEQUENCE OF:
(B)

PRIOR EXAMINATION REVIEW BY DME

BODY TAG CLOTHING
 XRAY (No. 13) FLUORO
 SPECIAL PROCESSING TAG MED. RECORDS
 AT SCENE PHOTOS (No.)

DUE TO, OR AS A CONSEQUENCE OF:
(C)

CASE CIRCUMSTANCES

EMBALMED
 DECOMPOSED
 > 24 HRS IN HOSPITAL
 OTHER: _____ (Reason)

DUE TO, OR AS A CONSEQUENCE OF:
(D)

OTHER CONDITIONS CONTRIBUTING BUT NOT RELATED TO THE IMMEDIATE CAUSE OF DEATH.

TYPING SPECIMEN

TYPING SPECIMEN TAKEN BY:
SOURCE: Chest

NATURAL SUICIDE HOMICIDE
 ACCIDENT COULD NOT BE DETERMINED

TOXICOLOGY SPECIMEN

COLLECTED BY:

HEART BLOOD STOMACH CONTENTS
 FEMORAL BLOOD UTRICULAR
TECHNIQUE: Chest

BILE BLOOD SPLEEN
 LIVER KIDNEY
 URINE _____

If other than natural causes, HOW DID INJURY OCCUR? with handguns

WAS OPERATION PERFORMED FOR ANY CONDITION STATED ABOVE: YES NO

TYPE OF SURGERY: _____ DATE: _____

ORGAN PROCUREMENT TECHNICIAN:

PREGNANCY IN LAST YEAR YES NO UNK NOT APPLICABLE

WITNESS TO AUTOPSY EVIDENCE RECOVERED AT AUTOPSY

Item Description: Sgt Frederick + PTA
From DA Inv

5 bullets/envel
→ Propbox
10/18/11

URINE GLUCOSE DIPSTICK RESULT: 4+ 3+ 2+ 1+ 0
TOX SPECIMEN RECONCILIATION BY:

HISTOLOGY

Regular (No.) Oversize (No.)
Histopath Cut: Autopsy Lab

TOXICOLOGY REQUESTS

FORM 3A: YES NO

NO TOXICOLOGY REQUESTED

SCREEN C H T S D

ALCOHOL ONLY
 CARBON MONOXIDE
 OTHER (Specify drug and tissue)

REQUESTED MATERIAL ON PENDING CASES

POLICE REPORT MED HISTORY
 TOX FOR COD HISTOLOGY
 TOX FOR R/O INVESTIGATIONS
 MICROBIOLOGY EYE PATH. CONS.
 RADIOLOGY CONS.
 CONSULT ON: _____
 BRAIN SUBMITTED
 NEURO CONSULT DME TO CUT
 CRIMINALISTICS
 GSR SEXUAL ASSAULT OTHER

RESIDENT _____ DME

16

2011-05-17
LAWIN, CARRELL L
-041
LASD-HOMI

117

EXTERNAL EXAM

- Sex
- Race
- Age
- Height
- Weight
- Hair
- Eyes
- Sclera
- Teeth
- Mouth
- Tongue
- Nose
- Chest
- Breasts
- Abdomen
- Scar
- Genital
- Edema
- Skin
- Decub
- HEART Wt.
- Pericard
- Hypert
- Dilat
- Muscle
- Valves
- Coronar

600cc Lt
hemorrh

290

RV 0.3
LV 1.3
Septum 1

AORTA
VESSELS

- LUNGS Wt
- R
- L
- Adhes
- Fluid
- Atelectasis
- Oedema
- Congest
- Consol
- Bronchi
- Nodes

- PHARYNX
- TRACHEA
- THYROID
- THYMUS
- LARYNX
- HYOID
- ABDOMINAL WALL FAT

ok

PERITONEUM

Fluid - ~50cc blood

LIVER Wt

1130

- Adhes
- Caps
- Lobul
- Fibros
- GB
- Calc
- Bile ducts

SPLEEN Wt

100

PANCREAS
ADRENALS
KIDNEYS Wt

R 100
L

BLADDER
GENITALIA

- Prost
- Testes
- Uterus
- Tubes
- Ovar

OESOPHAGUS
STOMACH

Contents empty

- DUOD & SM INT
- APPENDIX
- LARGE INT
- ABDOM NODES
- SKELETON

- Spine
- Marrow
- Rib Cage
- Long bones
- Pelvis

ok

30cc cloudy

ok

SCALP
CALVARIUM
BRAIN Wt

- Dura
- Fluid
- Ventric
- Vessels
- Middle ears
- Other

PITUITARY

SPINAL CORD

1 x 1/4 roughly
circular depress
fx of inner table (encroach
on brain)

TOXICOLOGY SPECIMENS

1" Contusion
cerebral

SECTIONS FOR
HISTOPATHOLOGY

MICROBIOLOGY

DIAGRAMS
X-RAYS

OTHER PROCEDURES

GROSS IMPRESSIONS

Post photos taken
before organ removal.
Consider diagrams are
final trajectory.

Date	Time	Deputy Medical Examiner
10/16/11	1800 end	Ry